

Medpor in Maxillofacial deformities: report of three cases

Received: 29 April 2009 / Accepted: 20 May 2009
© Association of Oral and Maxillofacial Surgeons of India 2009

Abstract

Objective This paper deals with the usefulness and versatility of the porous high-density polyethylene implants for correction of various facial deformities as an augmentation and an onlay graft material with its advantages.

Materials and methods Prefabricated porous high-density polyethylene implants were used in three patients (post-trauma facial deformity, Goldenhar syndrome, nasal deformity in cleft patient) for secondary reconstruction of orbital floor, depressed nose and supra-orbital ridge, augmentation of hypoplastic mandible and depressed nasal dorsum under general anaesthesia.

Results Good esthetic results were achieved in all the three patients treated with porous high-density polyethylene implants with no complications.

Conclusion Porous high-density polyethylene alloplastic implant is an excellent biomaterial for reconstruction of various facial deformities with many advantages over autogenous and other alloplastic materials.

Keywords Porous high-density polyethylene implants · Medpor Biomaterial · Orbital floor reconstruction · Goldenhar syndrome and mandibular augmentation

Introduction

Balance in facial proportions and facial esthetics can be achieved by use of the facial implants. These are required to achieve anatomical harmony in cases of trauma, congenital deformities or as in the cosmetic and aesthetic surgery. The malar eminence, chin and the nose are the common sites of implant placement in the cosmetic surgery.

Biomaterials have been the choice since long for facial reconstruction. For a biomaterial to be used for craniofacial reconstruction should meet several criteria. The biomaterial should be biocompatible with the surrounding tissues without eliciting any foreign body reaction and non-carcinogenic. Radiolucent for easy assessment within the body by radiographic means, easy to fabricate and shape to fit the deformity, maintaining volume resisting resorption and osteoactive. Also the biomaterial should be readily available and cost-effective.

The alloplastic materials used should be judged considering autogenous bone and the cartilage as the standard [1], since

facial implants are used to replace either of the two of the face. But, still autogenous bone and cartilage have their own drawbacks which include donor site morbidity, difficulty in shaping the graft, graft warpage, graft resorption and increased surgical time [2,3].

Many of the alloplastic biomaterials have inherent drawbacks. Silicone and methylmethacrylate cause resorption of underlying bone which aggravates deformity if implant removal is required due to infection or any other reason. They do not promote tissue ingrowth and cause capsulation and migration of the implant [4]. Encapsulation and predisposition to movement are responsible for the majority of late complications reported with smooth surface implants [5–13]. Hydroxyapatite biomaterial for cranial vault reconstruction shows no tissue or bone ingrowth [14].

Porous high density polyethylene, an alloplastic implant material offers many advantages as compared to other biomaterials. Porous high density polyethylene was developed in the early 1970s. Porous polyethylene is insoluble in tissue fluid, is not resorbed, and has

Andrade NN¹ · Kanchan Raikwar² ✉

¹ Head of the Department, Dept. of Oral and Maxillofacial Surgery

² Postgraduate student

Nair Hospital Dental College, Mumbai

Address for correspondence:

Kanchan Raikwar

B-2, Anant Smriti Apts

Datta Nagar Road,

New Katraj, Pune – 411 046.

Ph: 9371460469, 9326058525.

E-mail: kanchanraikwar@yahoo.com

demonstrated long-term structural stability when used as a facial skeleton only [15,16]. It is slightly flexible at the room temperature and when heated in hot water becomes malleable. It has high-tensile strength and readily available. It is available in various preformed shapes and can be easily cut through scalpel blade to shape and customize. Porous high density polyethylene has interconnecting network of pores which range from 150 to 368µm in diameter that encourages tissue ingrowth [17]. Rapid ingrowth of fibrous tissue with mature blood vessels and bone is demonstrated by the porous high density polyethylene [18]. Tissue ingrowth helps in integration of the implant to the surrounding tissues thereby reducing implant migration in comparison to silicon implants which develop a fibrous tissue capsule without fixation to adjacent skeleton [19]. The rapidity of vascularised tissue ingrowth provides resistance to infection as compared to other porous implants [20]. Histological examination of porous high density polyethylene implants have also revealed minimal inflammatory and foreign body reactions [18].




Fig. 1a Medpor for orbital floor reconstruction

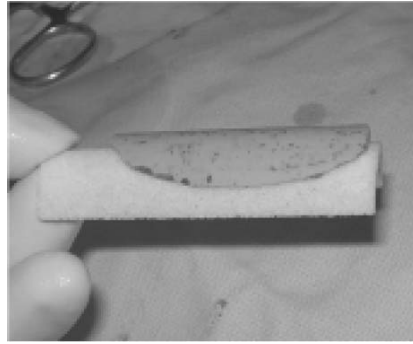


Fig. 1b Medpor nasal onlay implant with template

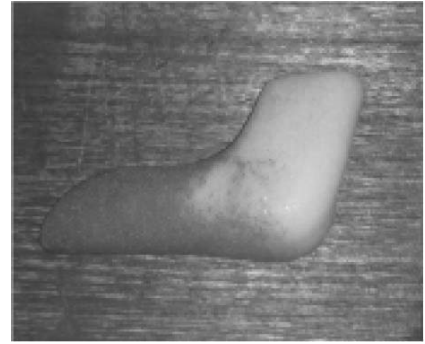


Fig. 1c Mandibular body and ramus onlay Medpor

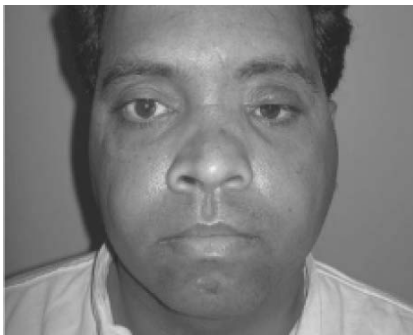

Fig. 2a Preoperative frontal view



Fig. 2b Preoperative lateral view

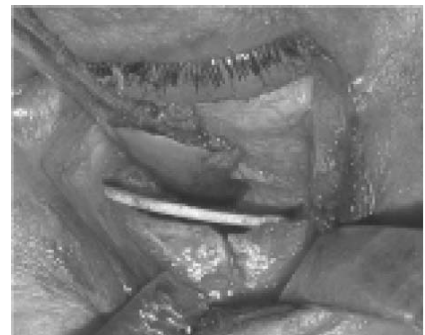

Fig. 2c Orbital floor reconstruction with Medpor implant

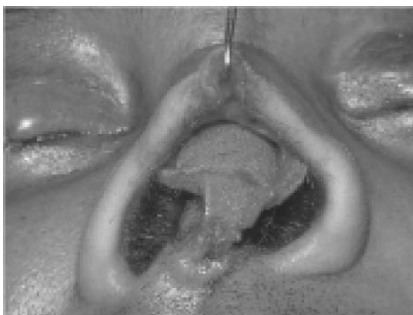

Fig. 2d Medpor nasal implant in place for correction of depressed dorsum

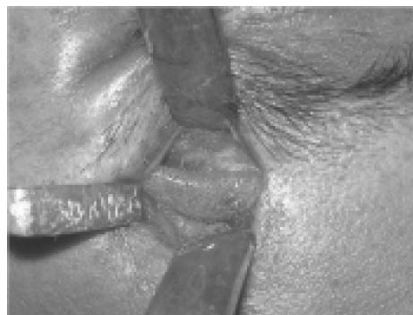


Fig. 2e Correction of depressed supraorbital ridge with part of orbital floor Medpor implant



Fig. 2f Postoperative frontal view



Fig. 2g Postoperative lateral view

Porous polyethylene is a reliable alloplastic material that can be satisfactorily used for craniofacial reconstruction. Case reports presented emphasize the usefulness of porous high density polyethylene implants in facial reconstruction in three patients with orbital

floor, nasal and supra-orbital ridge reconstruction in post-trauma case, mandibular augmentation in Goldenhar syndrome and correction of dorsal nasal deformity in operated case of cleft lip and palate.

Materials and methods

A total number of 3 patients coming to the Department of Oral and Maxillofacial Surgery at the Nair Hospital Dental College, Mumbai, with varying facial deformities were implanted with porous high-density polyethylene implants (Medpor Biomaterial; Porex Surgical Products Group). Total number of 5 sites in these 3 patients were implanted with prefabricated Medpor, except for one. In

the first case, orbital floor fracture, depressed supra-orbital ridge and nasal fracture were secondarily reconstructed. Second case involves mandibular ramus and posterior body augmentation in a Goldenhar syndrome patient with the reconstructive onlay shape graft. Third case involves correction of dorsal nasal deformity in an operated case of cleft lip and palate with a Medpor nasal dorsum shape onlay graft.

All patients were taken up for correction of facial deformities under general anaesthesia. All the augmentations achieved of the orbital floor, depressed nose and mandibular ramus and body were carried out through extra-oral incisions. All the onlay grafts were prefabricated ones (Figs. 1a to 1c) and were individually reshaped using scalpel blade as per the

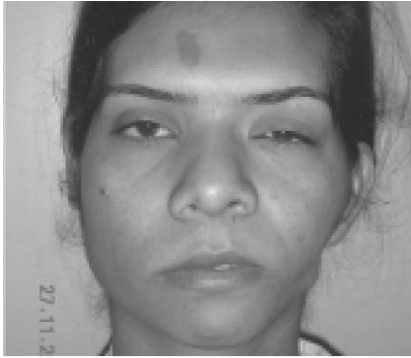

Fig. 3a Preoperative frontal view

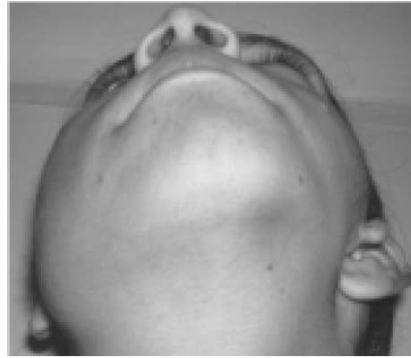

Fig. 3b Preoperative worm's view

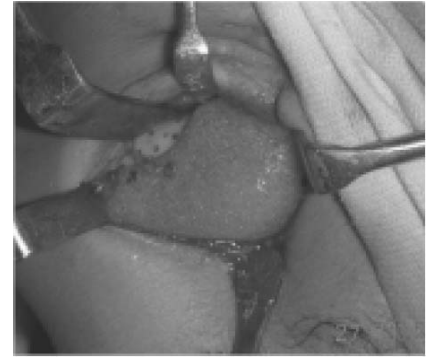


Fig. 3c Mandibular body and ramus only Medpor in place for augmentation

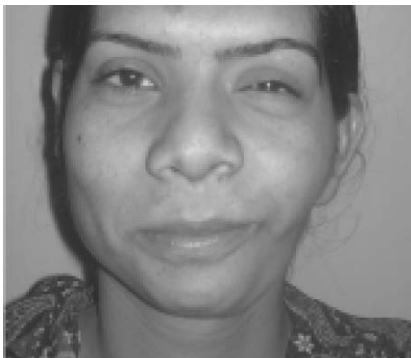

Fig. 3d Postoperative frontal view

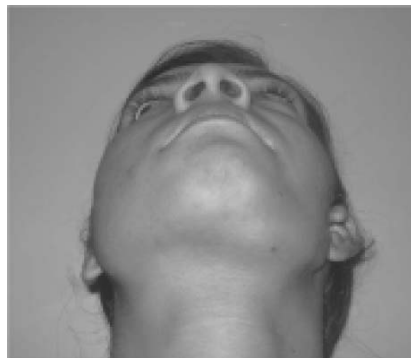


Fig. 3e Postoperative worm's view

requirement of the individual deformity. However, fortunately, the depressed supra-orbital ridge was augmented with a part of the left onlay graft used for the orbital floor augmentation and no special onlay graft was used. The onlay Medpor grafts were soaked in Gentamycin antibiotic and secured with suture fixation for immobilization with adequate soft tissue coverage.

Case reports

Case 1

A 33-years-old patient (Figs. 2a and 2b) met with a road traffic accident three months back with multiple malunited facial fractures almost involving all facial bones causing malocclusion, enophthalmos and depressed nasal dorsum. In the first stage patient was taken up for correction of malocclusion by open reduction and fixation of malunited Lefort I fracture. In the second stage was taken up for correction of depressed nasal dorsum and enophthalmos. He underwent secondary orbital floor reconstruction through an infraorbital incision with Medpor (Fig. 2c) and augmentation of depressed nasal deformity through a transcolumellar incision with a nasal onlay shape Medpor (Fig. 2d) both of which were shaped and

customized according to the defect. A part of the Medpor for the orbital floor reconstruction was used to augment the supra-orbital ridge (Fig. 2e) through the lateral brow incision.

Case 2

A 25-years-old patient suffering from Goldenhar Syndrome (Figs. 3a and 3b) desired correction of her facial deformity of hypoplastic left side. At the first stage patient was taken up for correction of gonial angle asymmetry through ramal distraction. At the second stage after three months she was taken up for distractor removal alongwith correction of maxillary occlusal cant with Lefort I osteotomy and free iliac crest graft. Finally patient was taken up for lateral augmentation of the mandibular body and the ramus through a standard post-ramal approach using basic design of mandibular ramus and body Medpor implant (Fig. 3c).

Case 3

A 14-years young girl (Figs. 4a and 4b), an operated case of unilateral cleft lip and palate with maxillary hypoplasia had come for correction of her dentofacial

deformities. At the first stage, patient was taken up for correction of maxillary hypoplasia with Lefort I level maxillary distraction. At the second stage patient was taken up for distraction appliance removal and rhinoplasty involving correction of depressed nasal dorsum using Medpor nasal dorsum onlay implant through a transcolumellar incision (Fig. 4c).

Results

Good facial contours with improved and significant esthetic results were achieved in all the three patients treated with porous polyethylene implants (Figs. 2f and 2g, 3d and 3e, 4d and 4e). Esthetic expectations of all the three patients were met with harmonious facial proportions.

No infections or hematomas occurred in any of the three patients. No implants had to be removed for repositioning or other reasons.

Discussion

Our experience with porous high density polyethylene implants in facial reconstruction in all the three patients has been satisfactory.

In the case of orbital floor reconstruction the vertical discrepancy of the globe due to orbital fracture was corrected satisfactorily. In operated cleft case and the trauma patient, the dorsal nasal deformity was corrected with obvious advantage of soft tissue ingrowth as opposed to other alloplastic materials. The disadvantage in correction of dorsal nasal deformity with this material is of the nasal rigidity which is however is not more than other autogenous materials. Alloplastic augmentation of the mandibular ramus and the body with porous high density polyethylene implant in the Goldenhar



Fig. 4a Preoperative frontal view

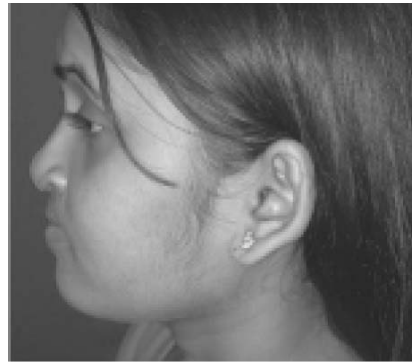

Fig. 4b Preoperative lateral view

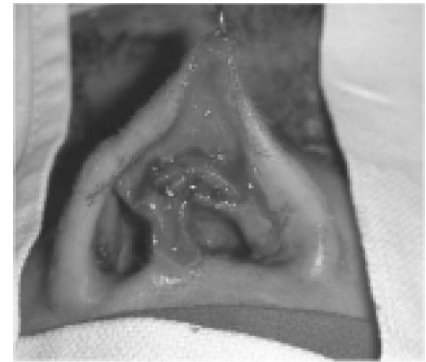


Fig. 4c Medpor nasal implant in place for correction of depressed dorsum

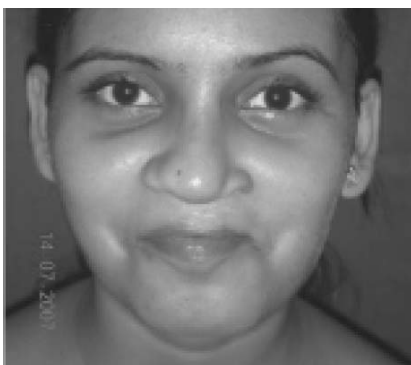


Fig. 4d Postoperative frontal view



Fig. 4e Postoperative lateral view

patient improved the lower third of the face and the overall appearance.

The results with the use of Medpor are satisfactory, with no morbidity. Porous polyethylene is a reliable alloplastic material that can be satisfactory used for craniofacial reconstruction [21,22]. Our experience has shown that porous high density polyethylene to be an excellent alloplastic bony replacement material and is promising to be an excellent biomaterial for craniofacial deformities.

References

1. Mass CS, Merwin GE, Wilson J, Frey MD, Maves MD (1990) Comparison of biomaterials for facial bone augmentation. *Arch Otolaryngol Head Neck Surg* 116(5): 551–556
2. Peer LA (1951) The fate of auogenous human bone grafts. *Br J Plast Surg* 3(4): 233–243
3. Brandon GE, Kern EB, Neel BN 3rd (1979) Autografts of uncrushed and crushed bone and cartilage. *Arch Otolaryngol* 105(2): 75–80
4. Wellisz T, Lawrence M, Jazayeri MA, Golshani S, Zhou ZY (1995) The effect of alloplastic implant onlays on bone in

- the rabbit mandible. *Plast Reconstr Surg* 96(4): 957–963
5. Rubin JP, Yaremchuk MJ (1997) Complications and toxicity of implantable biomaterials used in facial reconstructive and aesthetic surgery: A comprehensive review of the literature. *Plast Reconstr Surg* 100(5): 1336–1353
6. Kohn R, Romano PE, Puklin JE (1976) Lacrimal obstruction after migration of the orbital floor implant. *Am J Ophthalmol* 82(6): 934–936
7. Ridley MT, Jones RS (1978) Failure of silastic chin implant four years postoperatively. *J Oral Surg* 36(8): 616–617
8. Davis RM (1986) Late orbital implant migration. *Ann Ophthalmol* 18(6): 223–224
9. Peak J, Haria S, Sleeman D (1992) Facial pain due to a displaced orbital floor implant: Report of case. *J Oral Maxillofac Surg* 50(11): 1234–1235
10. Lipshutz H (1966) A clinical evaluation of subdermal and subcutaneous silicone implants. *Plast Reconstr Surg* 37(3): 249–250
11. Cohen SR, Mardach OL, Kawamoto HK Jr (1991) Chin disfigurement following removal of alloplastic chin implants. *Plast Reconstr Surg* 88(1): 62–66

12. Brown AE, Banks P (1993) Late extrusion of alloplastic orbital floor implants. *Br J Oral Maxillofac Surg* 31(3): 154–157
13. Whear NM, Cousley RR, Liew C, Henderson D (1993) Postoperative infection of Proplast facial implants. *Br J Oral Maxillofac Surg* 31(5): 292–295
14. Gosain AK (2005) Biomaterials for reconstruction of the cranial vault. *Plast Reconstr Surg* 116(2): 663–666
15. Yaremchuk MJ (2000) Mandibular augmentation. *Plast Reconstr Surg* 106(3): 697–706
16. Yaremchuk MJ (2001) Infraorbital rim augmentation. *Plast Reconstr Surg* 107(6): 1585–1592
17. Shanbag A, Freidman HI, Augustine J, Von Recum AF (1990) Evaluation of porous polyethylene for ear reconstruction. *Ann Plast Surg* 24(1): 32–39
18. Wellisz T, Kanel G, Anooshian RV (1993) Characteristic of tissue response to Medpore porous polyethylene implants in human facial skeleton. *J Long-Term Effects Med Implants* 3: 223
19. Wheeler DL, Eschbach EJ, Hoellrich RG, Montfort MJ, Chamberland DL (2000) Assesment of resorbable bioactive material for grafting of critical-size cancellous defects. *J Orthop Res.* 18(1): 140–148
20. Romano JJ, Liff NT, Manson PN (1993) Use of Medpore porous polyethylene implants in 140 patients with facial fractures. *J Craniofac Surg* 4(3): 142–147
21. Ozturk S, Sengezer M, Isik S, Turegun M, Deveci M, Cil Y (2005) Long-term outcomes of ultra-thin porous polyethylene implants used for reconstruction of orbital floor defects. *J Craniofac Surg* 16(6): 973–977
22. Cenzi R, Farina A, Zuccarino L, Carinci F (2005) Clinical outcome of 285 Medpor grafts used for craniofacial reconstruction. *J Craniofac Surg* 16(4): 526–530